



iUni[®]G2

SURGICAL TECHNIQUE GUIDE

Patient-specific UNICOMPARTMENTAL knee resurfacing system

FEMUR FIRST



iUni G2

UNICOMPARTMENTAL

Table of Contents

Introduction page 3

Preoperative Image Review..... page 6

Step 1: Femoral Preparation..... page 7

Step 2: Balancing the Knee page 11

Step 3: Tibial Preparation..... page 13

Step 4: Final Preparation..... page 15

Step 5: Cementing Implants..... page 17

Pre and Postoperative Coronal and Sagittal Views.....page 19

Introduction

The ConforMIS iUni® G2 (Generation 2) is a unicompartmental implant designed for the treatment of moderate to severe osteoarthritis isolated to the medial or lateral compartments of the knee. The iUni G2 represents a significant advancement in unicompartmental implant technology.

By utilizing proprietary iFit® image-to-implant technology and data from a patient's CT scan, implants are personalized for each patient. This personalized fit enables the implant to achieve precise anatomic fit with minimal bone resection. The accompanying patient-specific, disposable iJig® instrumentation and iView® planning images enable a simplified, reproducible surgical technique. They are employed in the five steps outlined to the right.

1. Femoral Preparation

2. Balancing the Knee

3. Tibial Preparation

4. Final Preparation

5. Cementing Implants

iUniG2

UNICOMPARTMENTAL

Surgeon Design Team

iUni® G2 Surgical Technique was developed in collaboration with:

Wolfgang Fitz, MD

Attending Surgeon at Brigham and Women's Hospital in Boston, MA, and Instructor of Orthopaedic Surgery at Harvard Medical School

Thomas Minas, MD, MS

Director of the Cartilage Repair Center at Brigham and Women's Hospital in Boston, MA, and Associate Professor of Orthopaedic Surgery at Harvard Medical School

The Femur First variation was developed in collaboration with:

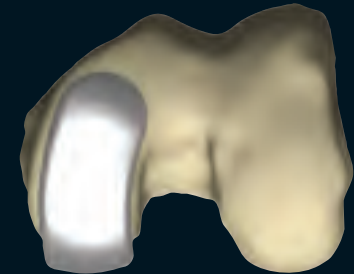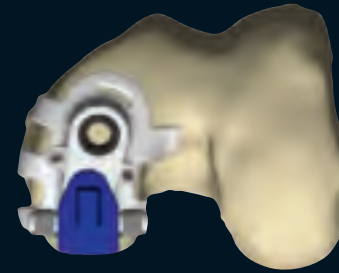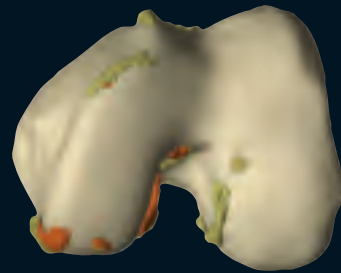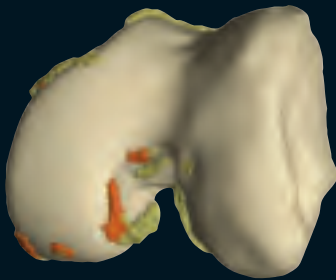Gregory Michael Martin, M.D.

Medical Director of the Orthopedic Institute at JFK Medical Center in Atlantis, FL

Ayaz Amir Biviji, M.D.

Attending Surgeon at Saint Joseph Hospital in Orange, CA

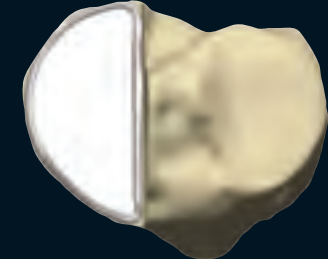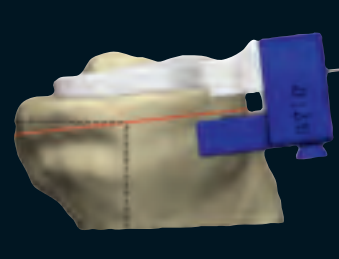
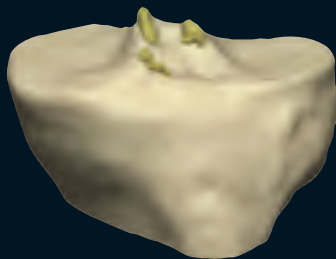Femoral Images



Orange colored osteophytes represent potential areas of interference with iJig

Posterior Cut: 4.9mm

Tibial Images

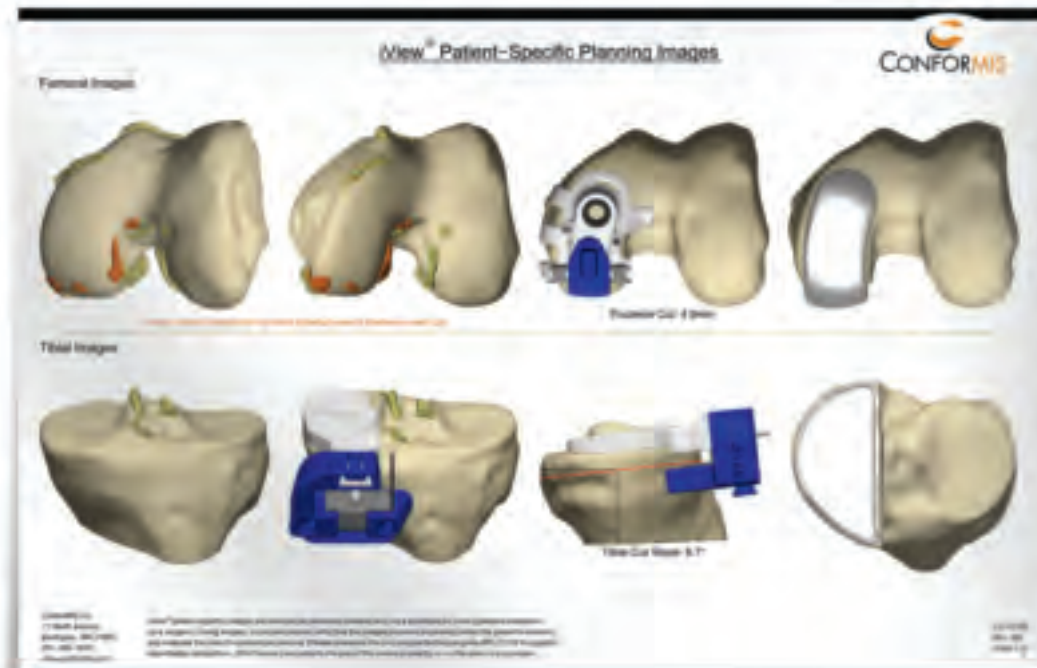


Tibial Cut Slope: 6.7°

Preoperative Image Review

iView® patient-specific planning images are included with each implant and are also available preoperatively from ConforMIS. The images provide patient-specific tibial and femoral osteophyte information, the tibial cut slope, posterior femoral resection value, and final implant positioning.

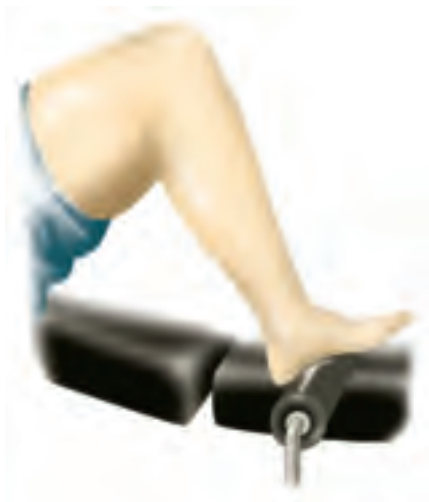iView patient-specific planning images are intended as reference material and not a substitute for intra-operative evaluation by a surgeon. During surgery, physicians should verify that the images provided accurately reflect the patient's anatomy and evaluate the knee for osteophyte removal.



iUniG2

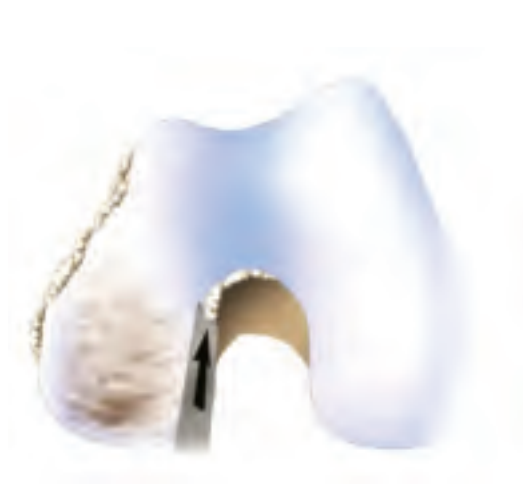UNICOMPARTMENTAL

Step 1 FEMORAL PREPARATION



Positioning

Position the patient supine on the operating table with a foot attachment that facilitates 90° of flexion. After a short midline skin incision, perform a medial arthrotomy (for a lateral case perform a lateral arthrotomy).

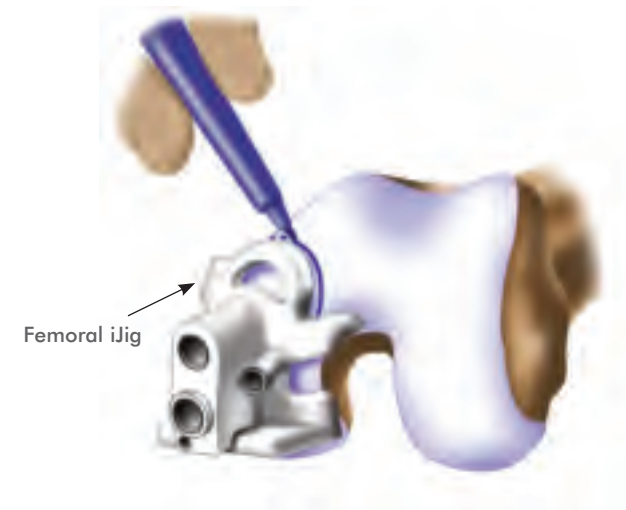

1. Remove all femoral and tibial osteophytes, including soft tissue and osteophytes in the intercondylar notch (i.e., conservative notchplasty). An osteotome and/or rongeur may be used for osteophyte removal.

Remove osteophytes from edges of the femoral condyle down to subchondral bone.

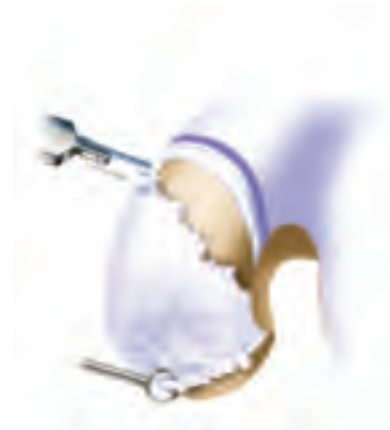Proper removal of osteophytes will facilitate accurate iJig alignment and orientation.

Overly aggressive peripheral osteophyte removal may result in less precise iJig fit and the appearance of slight implant overhang.



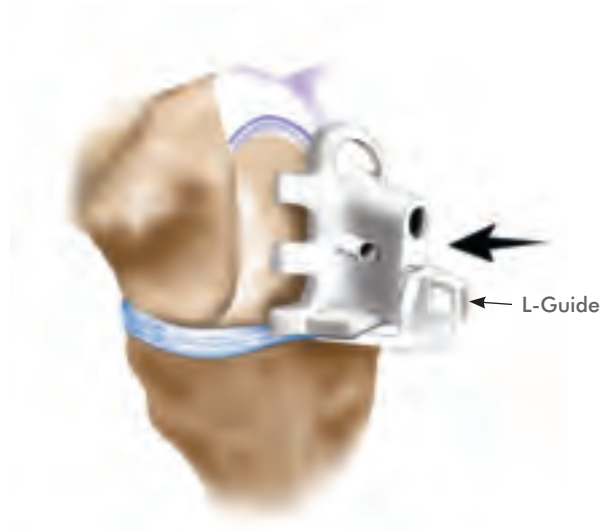
2. Place the Femoral iJig on the condyle and mark the anterior margin of the Femoral iJig. A marker is recommended, rather than a bovie or blade to prevent damage to healthy cartilage.

In most cases, the anterior edge of the Femoral iJig seats approximately 1mm inferior to the linea terminalis.



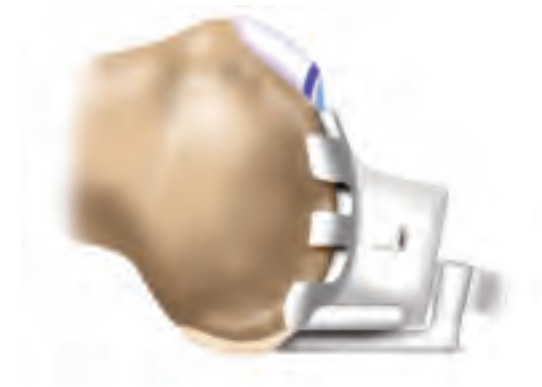3. Remove all cartilage beginning about 2mm inferior to the mark, including off the posterior condyle, using a 10mm blade and a curved elevator or ring curette. Femoral cartilage removal is easiest in deep flexion.

Beginning cartilage removal inferior to the linea terminalis ensures a smooth transition from the implant to cartilage. Removal of additional cartilage can be completed during femoral implant trialing.



4. Attach the L-Guide to the inferior pin hole on the Femoral iJig and place it on the condyle with the knee in approximately 90° of flexion.

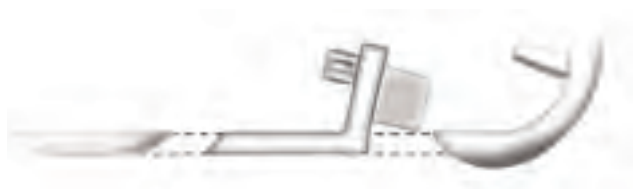Carefully remove any cartilage from the transition and anterior margin that may keep the Femoral iJig from seating against subchondral bone. A smooth transition from the cartilage to the Femoral iJig is desired.



5. Verify that the Femoral iJig is stable in its AP and ML position. The Femoral iJig should also be flat against subchondral bone and central on the condyle as seen through the anterior and peripheral openings.

Confirm that cartilage removal at the superior margin provides a smooth transition now that the Femoral iJig is in its final position.

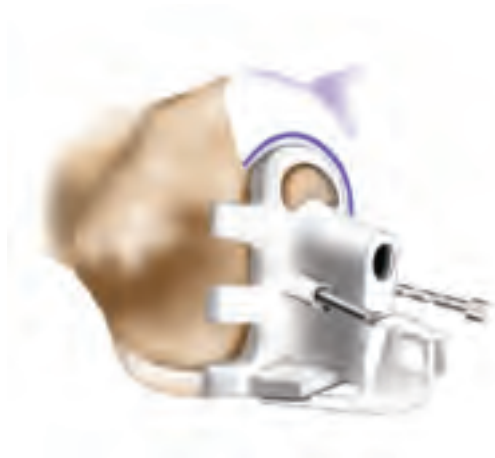Step 1 FEMORAL PREPARATION



6. Confirm the target posterior femoral resection, which equals the thickness of the L-Guide. If needed, the L-Guide can be removed for better visualization. If the projected resection appears too thick, confirm all cartilage is removed from the posterior condyle.

Thickness of the posterior femoral resection is provided with the iView patient-specific planning images.

The posterior implant thickness is approximately equal to the sum of the posterior femoral resection and normal femoral cartilage.

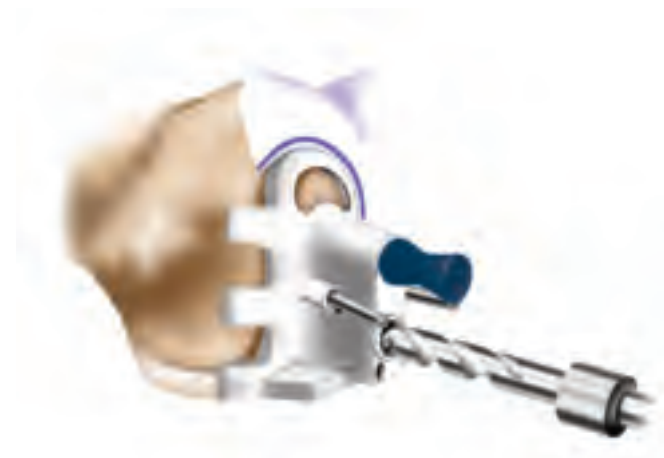

7. Using the 3mm drill bit, drill and pin two Stabilization Holes on the Femoral iJig. Drill to depth required to adequately fixate the Femoral iJig.

Depending on the configuration of the Femoral iJig there are either two or three Stabilization Holes provided. Determine which two to use based on general fit and accessibility.

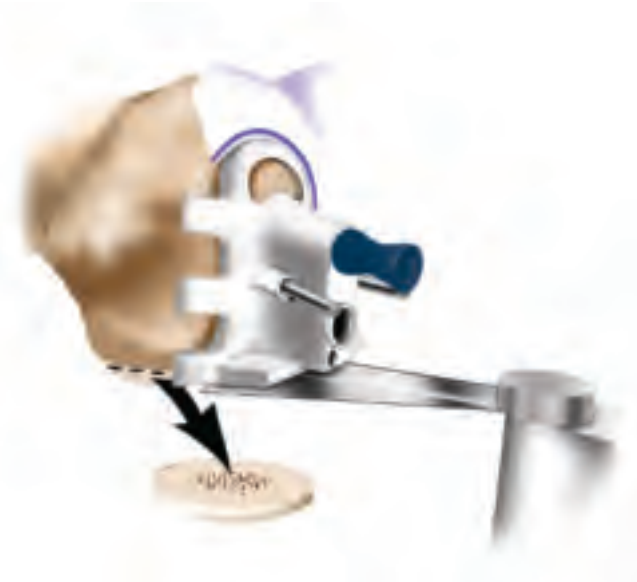Visually reconfirm the thickness of the planned posterior femoral resection to the value provided in the iView patient-specific planning images.

If required, the pins in the Stabilization Hole can be removed and reset until the optimal position is obtained.



8. Using the 6mm drill bit, drill and pin the superior peg hole on the Femoral iJig. Then drill the inferior peg hole after removing the L-Guide. (Do not pin the inferior peg hole.)

The drill bit has a hard stop; drill to the hard stop. Pin the superior peg hole using the blue disposable femoral peg marked "F".



- 9.** Perform the posterior femoral resection, referencing off the flat cut-guide surface, and remove bone.

Begin resection with the saw blade angled up slightly and then straighten the blade for a flat resection. This will prevent the saw blade from skiving off the posterior condyle and producing an angled resection.

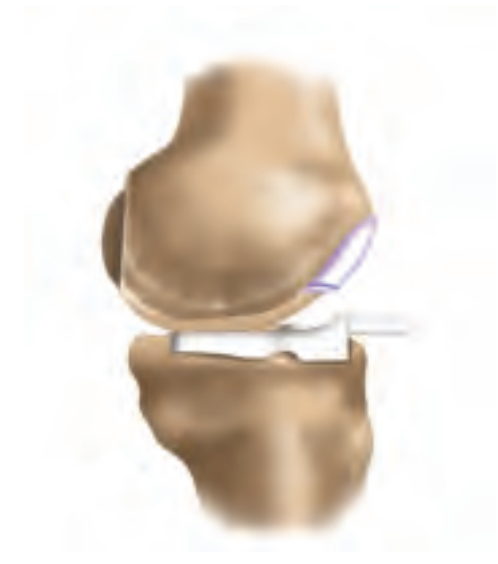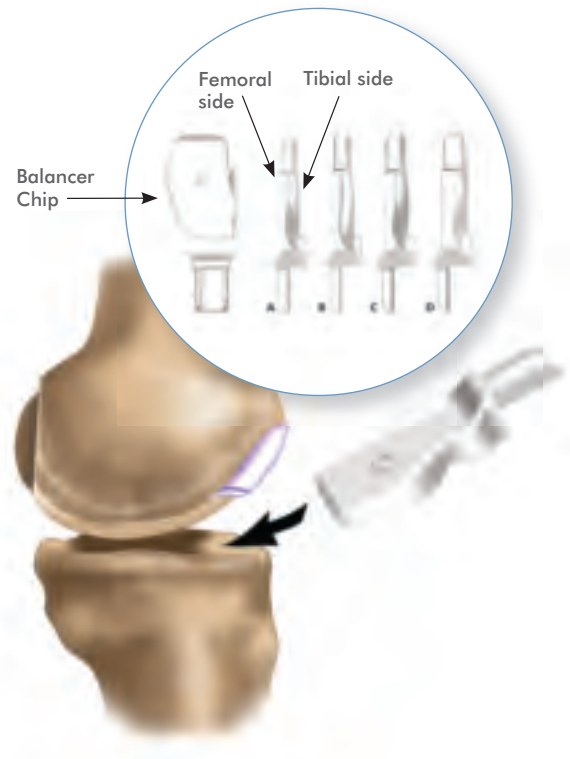
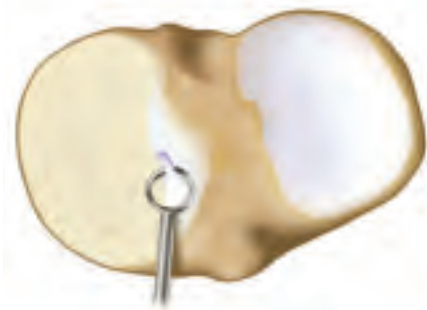- 10.** Confirm accuracy of the femoral resection by comparing the resected bone segment to the femoral resection value provided in the iView.

The femoral resection value provided in the iView patient-specific planning images will be equal to the measured thickness of the resected bone segment plus the thickness of the saw blade.

If needed, additional posterior femoral resections can be performed until the target resection value is achieved (For example, if the original resection is too conservative). To do this, remove, reposition and re-fixate the Femoral iJig, then perform additional resections.

- If visualization is a challenge, carefully peel back the capsule away from the proximal tibia to the MCL.
 - The MCL can be released away from the tibia using a curved $\frac{1}{4}$ " osteotome, taking care not to damage any fibers.
- For a lateral iUni, dislocating the patella from the notch using a bent Hohmann may improve access and visualization.
- Failure to remove osteophytes may result in improper Balancer Chip selection and a more aggressive tibial resection or looser joint than planned.
- After the posterior femoral cut has been made, the resected segment can be evaluated to observe if all cartilage was removed from the surface that otherwise would have been in contact with the Balancer Chip during soft tissue balancing.
- If adequate fixation can be obtained with the 3mm Stabilization Holes, the femoral resection can be performed prior to drilling the 6mm peg holes.

Step 2 BALANCING THE KNEE



1. Remove meniscus and scrape any remaining cartilage from the tibial plateau, as well as the tibial spine on the affected side. Remove all tibial osteophytes that may tension the ligaments or interfere with Balancer Chip placement.

Finish cartilage removal using a 5mm ring/open curette down to subchondral bone.

2. Select an appropriate Balancer Chip from 4 available sizes to achieve desired ligament tensioning. The Balancer Chips are designated A, B, C, and D and increase in thickness by 1 mm incrementally.

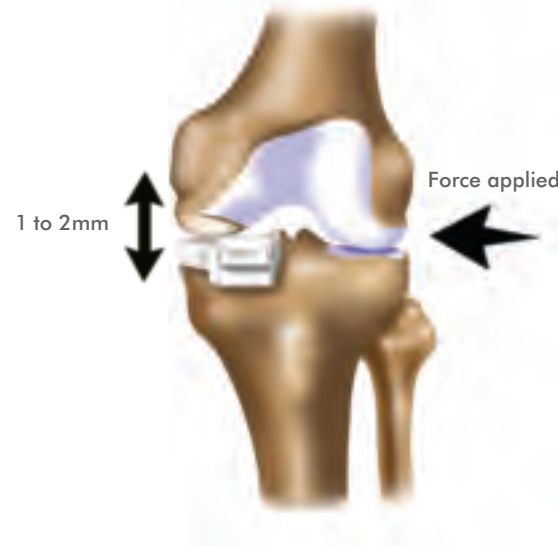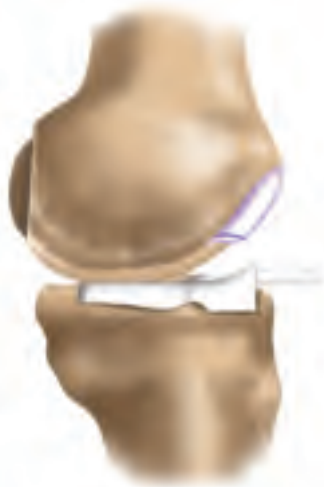Insert the selected Balancer Chip between the femur and tibia with the flat (lettered) surface facing up.

The superior surface has a flat geometry to allow referencing off the distal femoral condylar surface. The inferior surface is designed to conform closely to the tibial surface and will self-seat into a stable position.

3. With the knee in extension evaluate desired tensioning.

Most patients will be properly balanced using a B or C Chip. If an A Chip seems to provide the best balancing, confirm that all tibial osteophytes and soft tissue have been removed and rebalance before proceeding.

The thicker Balancer Chips (e.g., D Chip) will result in less tibial bone resection.



4. If the selected Balancer Chip is expelled, revisit the tibia and femur for any remaining posterior meniscus or cartilage.

The Balancer Chip is designed from the patient's CT scan and needs to be touching subchondral bone on the tibial plateau and distal femoral condyle.

5. Apply valgus/varus pressure in extension with the selected Balancer Chip in place. Joint play of 1-2mm for the medial compartment and 2-3mm for the lateral compartment is desired. A tight joint may lead to the overstuffing of the contralateral compartment.

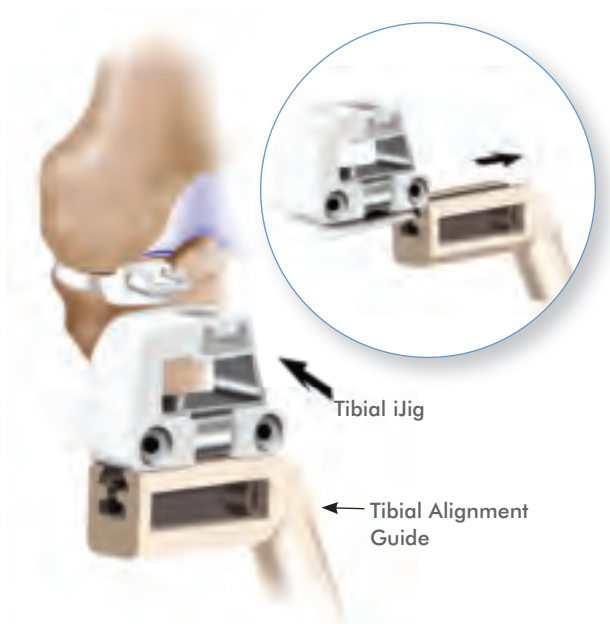
Repeat until the Balancer Chip which provides optimal ligament tensioning is identified.

Retractors must be removed during balancing to ensure the collateral ligaments are not tensioned. If using a leg holder, ensure it is not affecting soft tissue balancing.

When in flexion, the joint will feel lax due to the posterior femoral resection.

- Insufficient cartilage removal may result in the use of a suboptimal Balancer Chip. Remaining cartilage on the tibial spine or plateau may also rotate the Balancer Chip.
- A complete meniscectomy will facilitate easier Balancer Chip placement.
- The posterior meniscus can keep the Balancer Chip from seating properly and may need to be removed. A laminar spreader can provide access to the posterior aspect of the knee and facilitate removal of the meniscal horn.
- Use a marker pen to label the Balancer Chip letter (A, B, C, or D) on the superior surface to facilitate easier identification during surgery.
- If the Balancer Chip appears malrotated and is not flush on the peripheral rim of the tibia, look for an anterior tibial osteophyte or soft tissue that may be keeping the Balancer Chip from seating flush against the cortex.
- The peripheral seating of the Balancer Chip along the tibial plateau can be confirmed by running your finger along the rim.

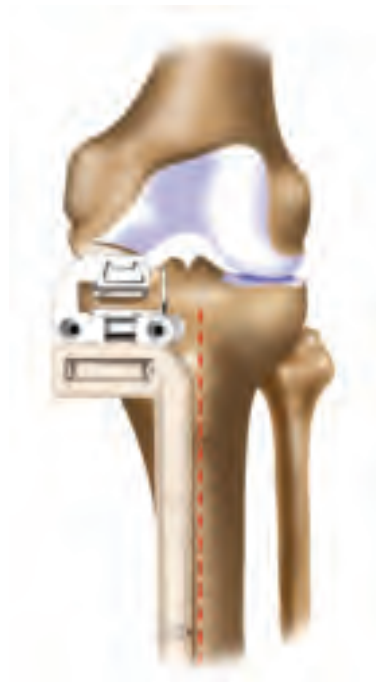Step 3 TIBIAL PREPARATION



1. Slide the dovetail feature of the Tibial iJig onto the Tibial Alignment Guide.

With the knee in extension, slide the Tibial iJig onto the post on the front of the Balancer Chip.

Seat the Tibial iJig flush against the anterior tibial surface. If the Tibial iJig does not rest flat against the surface, revisit the tibia and remove any anteromedial osteophytes.



2. Verify that the Tibial Alignment Guide is parallel with respect to the tibial eminence and the Balancer Chip is seated flat on the tibial plateau. This will confirm the position of the Tibial iJig prior to drilling the pin holes.



3. Using the 3mm drill bit, drill and pin the Tibial iJig. The Tibial Alignment Guide can then be removed if desired.

The central tibial pin is designed to enter under the contralateral compartment to avoid drilling a second hole under the affected compartment.



4. With the knee in approximately 90° of flexion, perform a sagittal (vertical) tibial cut using the Tibial iJig.

The saw blade needs to be flat against the metal cut. For medial repairs, the saw blade will be approximately at the apex of the tibial spine. In some cases, a few ACL fibers may be resected.

The reciprocating saw blade can be left in to protect the ACL insertion while performing the axial (horizontal) cut.

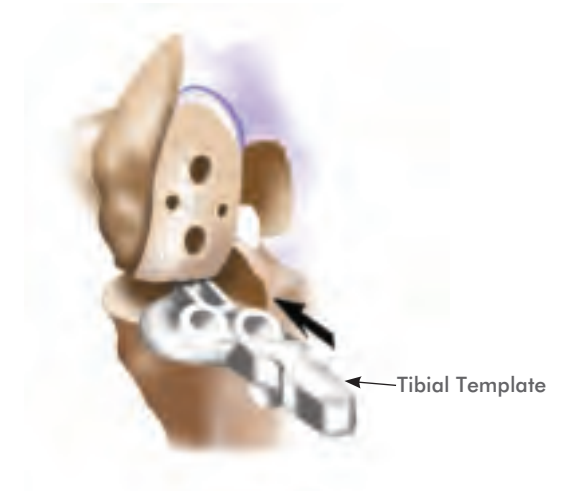
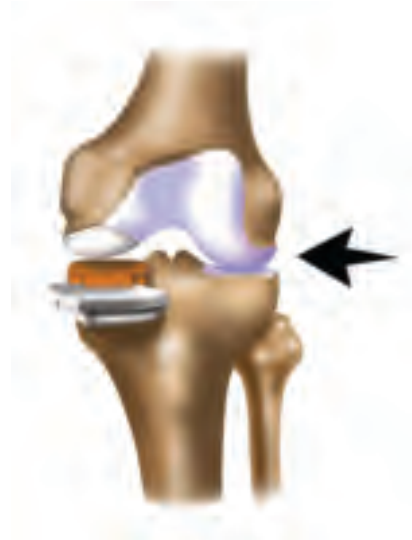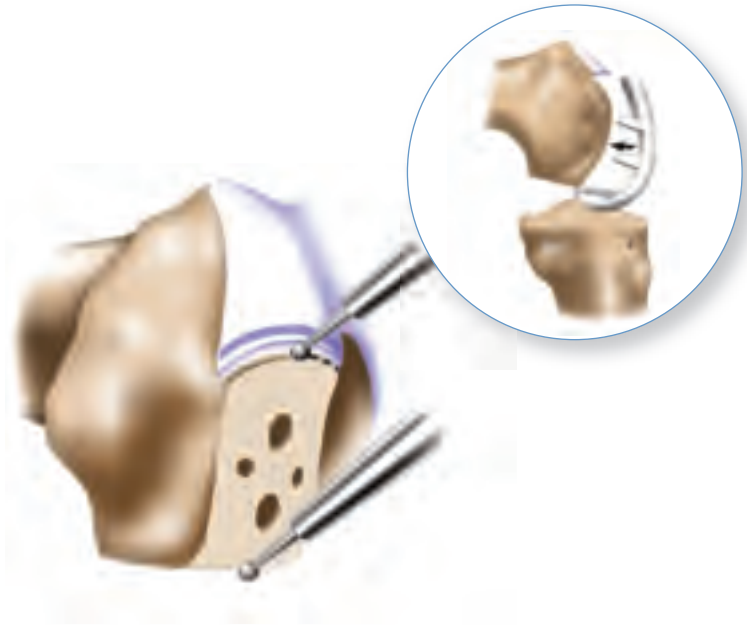


5. Perform an axial (horizontal) tibial cut using the Tibial iJig. Remove the Tibial iJig followed by removing the resected bone segment. Any remaining posterior meniscus can now be removed.

Once the tibial resections has been made, the Balancer Chip can be placed back on the resected segment to confirm if all cartilage was removed. This will help in visualizing cartilage removal for future cases.

- The angle of the posterior cut slope is provided on the iView patient-specific planning images. The posterior slope can be visually confirmed by viewing the sagittal position of the Tibial Alignment Guide.
- If preferred, a single pin under the contralateral compartment may provide adequate stability for the Tibial iJig, obviating the need for drilling two pin holes.
- Attaching a Kocher to the 3mm pin and against the Tibial iJig will help further stabilize the Tibial iJig during sawing.
- The Tibial Template can be measured for A/P length to get the posterior depth of the horizontal cut, and then the saw blade can be marked to the same depth to avoid going too deep during resection.
- Once femoral condylar and tibial resections have been made, revisit the “rear” of posterior condyle for any large osteophytes.

Step 4 FINAL PREPARATION



1. With the knee in flexion, round the resulting anterior sharp corner from the femoral bone cut with a 5mm burr, rasp, or curette. The femoral implant has a radius at the mating anterior edge of the femoral cut.

Place the Femoral Trial or the femoral implant on the condyle and mark the transition zone between the trial and intact femoral cartilage using a marker.

Create inset for anterior margin of femoral implant with a burr. The most anterior edge of the component submerges 3-4mm below the subchondral bone, with a taper beginning approximately 7-9mm inferior to the intact cartilage.

Verify shape and depth of the burred inset with the Femoral Trial or the Femoral Implant.

2. With the Femoral Trial or Femoral Implant in place, insert the orange 8mm Spacer Block and evaluate the balance in flexion and extension.

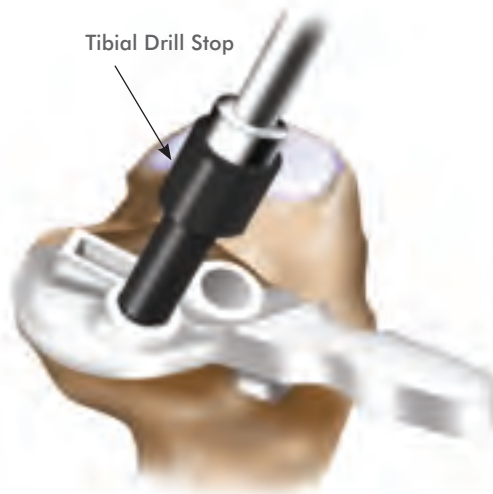If tight in flexion and extension, resect an additional 1-2mm off of the tibia while maintaining the same tibial cut slope. A 2mm generic tibial re-cut guide is included with the Tibial Alignment Guide and can be used for additional resection.

If loose, insert the blue 10mm Spacer Block and evaluate balance.

The orange 8mm Spacer Block corresponds to the combined thickness of the metal tibial implant component and the 6mm poly. The blue 10mm Spacer Block corresponds to the 8mm poly.

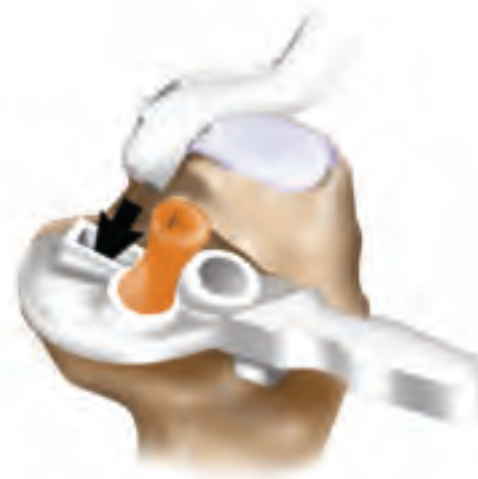3. With the knee in flexion, insert the Tibial Template and confirm appropriate fit with respect to the profile of the tibial cut. The Tibial Template profile matches the profile of the Tibial Tray.

The Tibial Implant is designed to maximize coverage of the affected compartment. The tibial resection may appear large due to the vertical cut being at, or close to, the apex of the tibial spine.



4. Place the provided Tibial Drill Stop onto the 6mm drill bit for the tibial preparation. The Tibial Drill Stop is located on the 3mm drill bit in each implant kit.

Place the Tibial Template flat against the vertical resection so it follows the outline of the cortical rim. Drill and pin the posterior (peripheral) hole and then drill the anterior peg hole. The orange disposable tibial peg is marked "T".

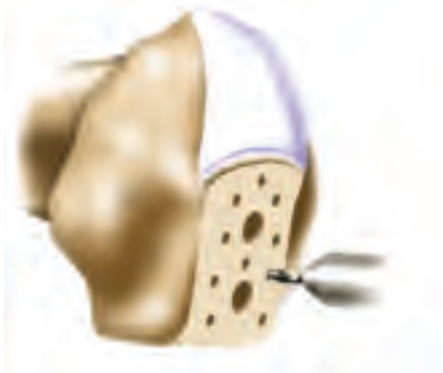

5. Create a keel hole using the Tibial Keel Punch preparation tool or a 1/4" osteotome.

The Tibial Keel Punch should be inserted with the curve facing out and with the handle angled parallel to the tibial peg. Impact the Keel Punch by striking at proximal end with a mallet.

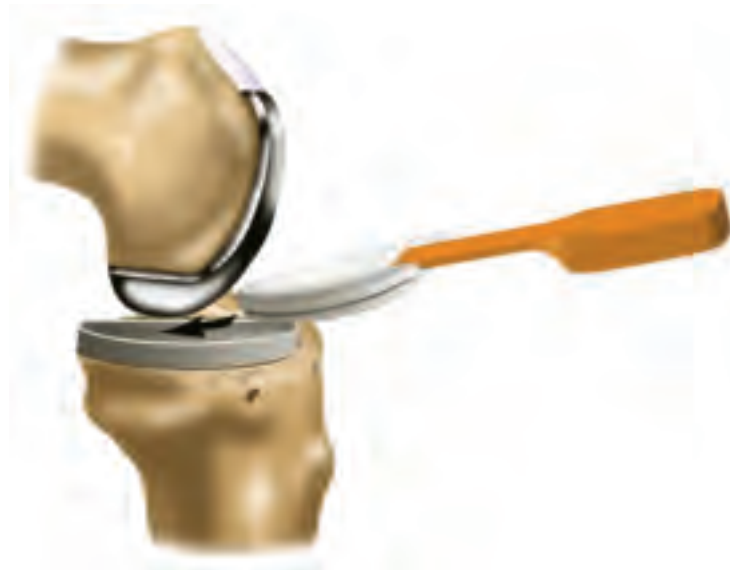- Putting the knee in deep flexion will improve access and visualization.
- If needed, the femoral implant may be placed into position and impacted using the supplied Femoral Impactor Tip to mark optimal location to burr the implant/cartilage transition zone.
- Rotating the tibia externally or internally may facilitate easier insertion of the Tibial Template and preparation of the tibia for the implant.
- Putting pressure on the Tibial Template against the sagittal cut may help with stability.
- It is acceptable to have up to 1mm of overhang. Revisit the sagittal cut if excessive overhang is observed. If there is slight overhang, a rasp can be used against the tibial spine.
- In the event an underhang is observed, position the Tibial Template so it sits on the cortical rim.
 - The reciprocating saw blade can be placed along the tibial spine to create space and position the Tibial Template on the cortical rim.
- If anterolateral overhang is observed, confirm that the Tibial Template stop is seated flat against the anterior tibia.
- An osteotome placed under the edge of the femoral trial can be used to remove the component.

Step 5 CEMENTING IMPLANTS



1. Using the perforator drill bit, drill approximately 8 to 10 cement holes to enhance cement interdigitation on the femoral cortical surface.

Irrigate the joint.

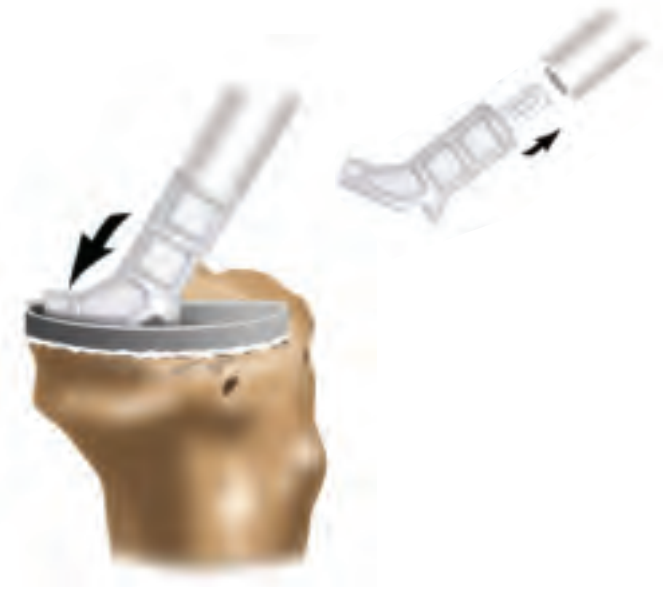

2. Place the Tibial Tray into position followed by the Femoral Trial or Femoral Implant. Insert a 6 or 8mm Trial Insert, corresponding to the Spacer Block used in order to confirm optimal balancing. Take care not to damage the articulating surface on the femoral implant during insertion.

Remove implants, femur first.

Combined with the 2mm Tibial Tray thickness, 6 and 8mm trials will correspond to the 8 and 10mm Spacer Blocks, respectively.

Metal implants used for trialing should be thoroughly cleaned and dried before cementing.



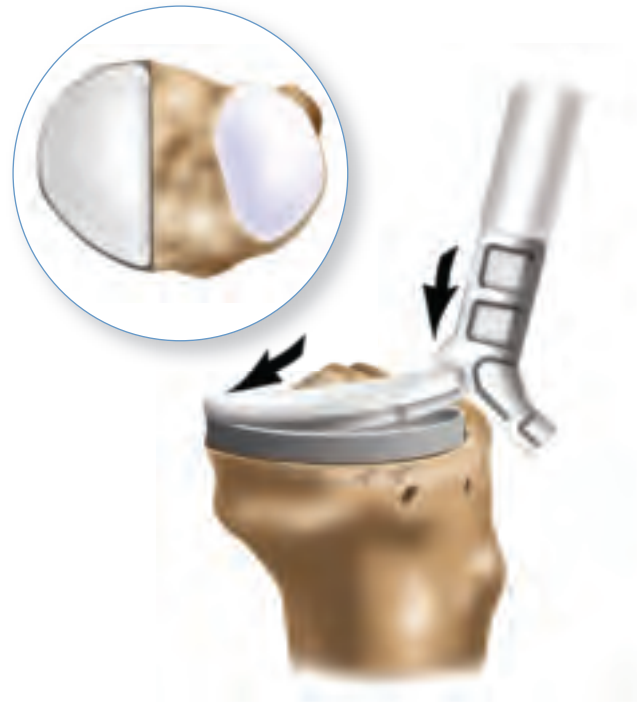3. Apply a layer of cement (less cement posteriorly) to the tibia, filling holes and covering bone surface.

Insert the Tibial Tray at an angle and press down such that excess cement extrudes anteriorly. Impact Tibial Tray using Tibial Impactor Tip.

Remove any residual extruded cement from around the implant with consideration for any cement that may have extruded posteriorly.

TECHNIQUE TIPS

- Mark the corresponding Trial Insert (6 or 8) on the superior surface to facilitate easier identification during surgery.
- An osteotome carefully placed under the edge of the femoral implant can be used to remove component after trialing.
- While cementing the Tibial Tray, an osteotome placed between the femur and Tibial Tray can be used to apply posterior to anterior pressure and extrude cement anteriorly.



- 4.** Apply a layer of cement to the femur, filling holes and covering bone surface. Impact the Femoral Implant using the Femoral Impactor Tip.

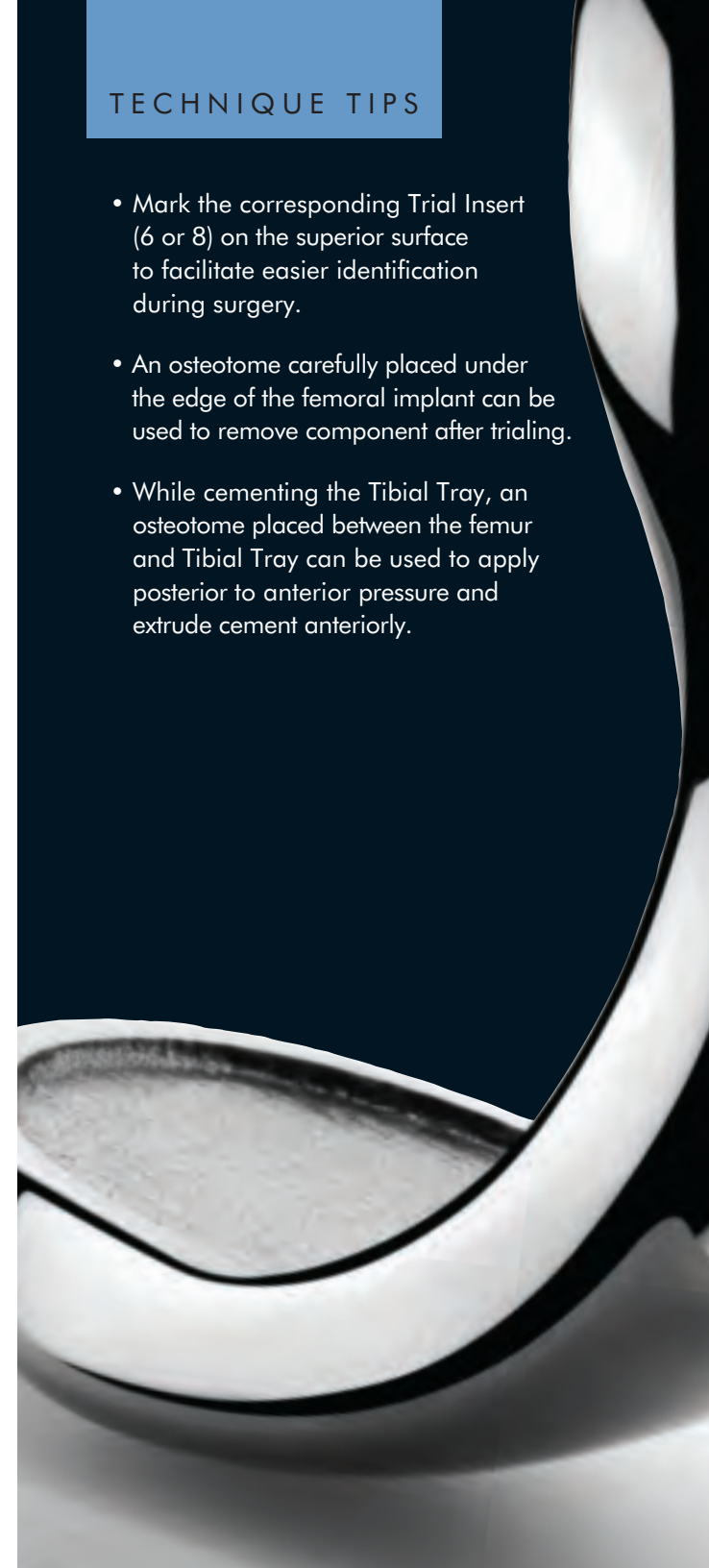Insert the selected Trial Insert and bring knee into 30° flexion, allowing equal pressurization of the components. Do not flex and extend knee while cement is setting.

Remove any residual extruded cement from around the implant.

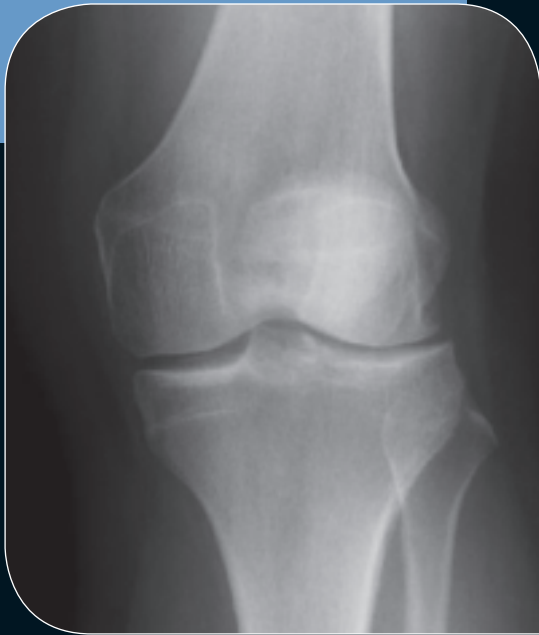- 5.** Remove the Trial Insert and check for posteriorly extruded cement.

Insert the selected poly size, posterior end first, at an angle. Snap poly into place by pushing down on the anterior edge with the heel of the Tibial Impactor Tip.

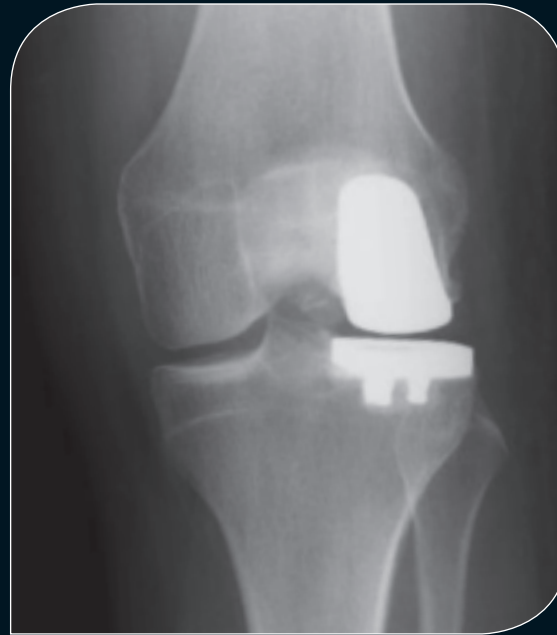If the poly does not lock into place, feel the back of the tray to check for a discontinuity between the tray and the poly. If there is a discontinuity, apply pressure to the outer edge of the poly as indicated in the image above.



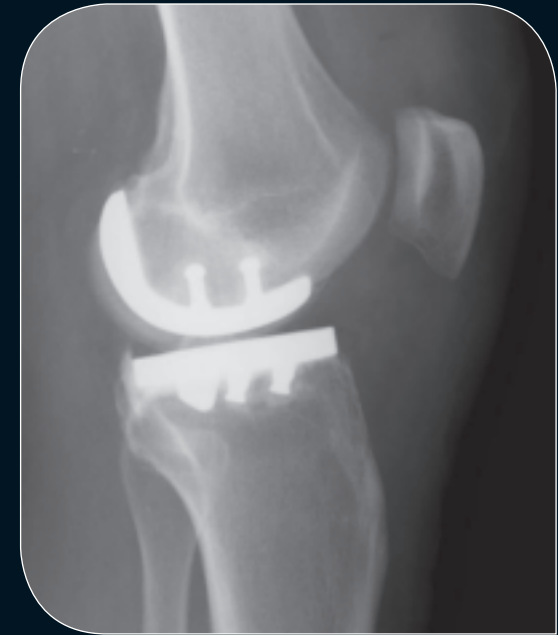Pre and Postoperative Coronal and Sagittal Views



Preoperative X-ray



Postoperative Coronal X-ray



Postoperative Sagittal X-ray

Intended Use

The ConforMIS Unicondylar Knee Repair System (iUni G2) is intended for use in one compartment of the osteoarthritic knee to replace the damaged area of the articular surface in patients with evidence of adequate healthy bone sufficient for support of the implanted components.

Candidates for unicondylar knee repair include those with:


- Joint impairment due to osteoarthritis or traumatic arthritis of the knee
- Previous femoral condyle or tibial plateau fracture, creating loss of function
- Valgus or varus deformity of the knee.
- Revision procedures provided that anatomic landmarks necessary for alignment and positioning of the implant are identifiable on patient imaging scans.

This implant is intended for cemented use only.

Contraindications

The following conditions are contraindications for unicondylar knee repair.

- Active or recent local or systemic infection.
- Loss of bone or musculature, osteoporosis, neuromuscular, or vascular compromise in the area of the joint to be operated to an extent that the procedure is unjustified.
- Severe instability due to advanced loss of osteochondral structure.
- Absence of collateral ligament integrity.
- Severe ($> 15^\circ$) fixed valgus or varus deformity.





ConforMIS, Inc. • 28 Crosby Drive • Bedford, MA 01730, USA • Phone: 781.345.9001 • Fax: 781.345.0147

www.conformis.com

Wear optimized implant design • Stronger, smarter instrumentation
iView patient-specific planning images



Authorized Representative: Medical Device Safety Service, GMBH
Schiffgraben 41, 30175 Hannover, Germany
Phone: +49 (511) 6262.8630
Fax: +49 (511) 6262.8633

iUni, iJig, iView and ConforMIS are registered trademarks of ConforMIS. Images by Dan Nichols.
CAUTION: USA federal law restricts this device to sale by or on the order of a physician.
The ConforMIS unicondylar knee-repair system (iUni G2) is intended for use only by medically trained physicians.

MK-02621-AB 02/13 | © 2012. ConforMIS, Inc.